



SimpliCT® clinical case report: Infected aortic aneurism sack

Courtesy of University of Copenhagen

Case history:

A 67 year old male having an infected aortic sack following an insertion of Aorto-bi-iliac bypass.

Procedure details:

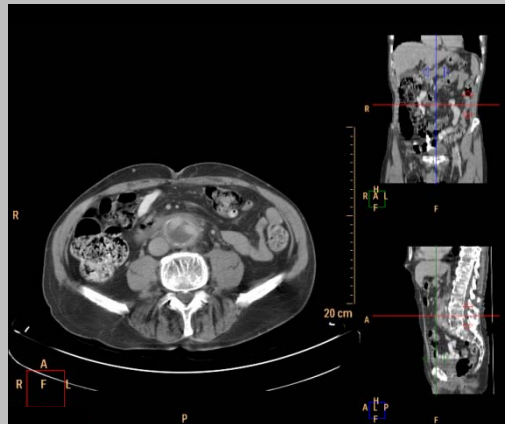
7 French one-step catheter was inserted using SimpliCT® as laser guide. The target was hit in one pass and pus was drained. Local antibiotics was administered. Depth of needle was 15 cm and point of entry chosen avoid perforation of guts and larger blood vessels

Comment:

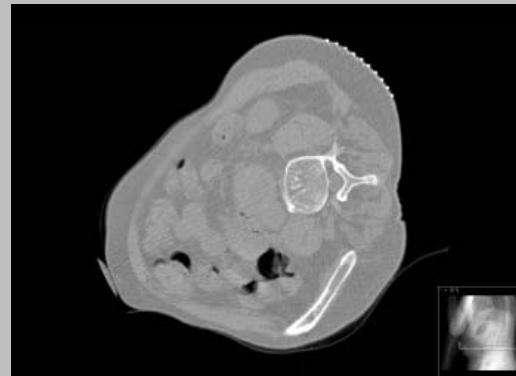SimpliCT® offered indispensable help for the accurate placement of the needle in one pass. Without the help of SimpliCT®, the patient would have needed a complicated open procedure.

Acknowledgement:

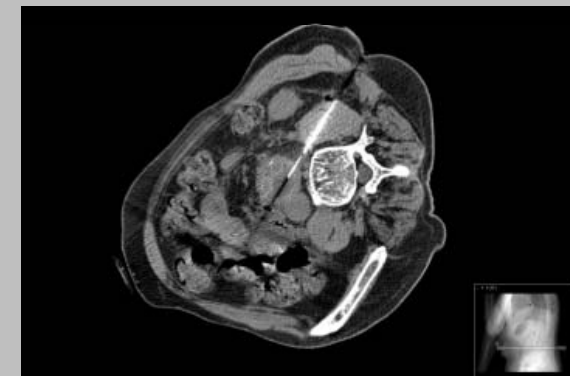Courtesy of Peter Sand Myschetzky, M.D, University of Copenhagen



Pre-procedure CT scan with contrast



Pre-procedure CT scan



Control CT scan after needle insertion

All images courtesy of Peter Sand Myschetzky, M.D., Dept. of Radiology, County Hospital in Gentofte, University of Copenhagen, Denmark